



ACADEMIC
PRESS

Available online at www.sciencedirect.com

SCIENCE @ DIRECT®

NeuroImage

NeuroImage 19 (2003) 906–912

www.elsevier.com/locate/ynimg

Representation of different trigeminal divisions within the primary and secondary human somatosensory cortex

G.D. Iannetti,^a C.A. Porro,^b P. Pantano,^a P.L. Romanelli,^a F. Galeotti,^a and G. Cruccu^{a,*}

^a Dipartimento Scienze Neurologiche, Università La Sapienza, Roma, Italy

^b Dipartimento di Scienze e Tecnologie Biomediche, Università di Udine, Italy

Received 8 July 2002; revised 12 December 2002; accepted 23 January 2003

Abstract

Clinical, neurophysiological, and neuroimaging studies have yielded controversial results about the representation of the face in the somatosensory cortex. To clarify this issue we mechanically stimulated the left forehead (ophthalmic trigeminal division, V1) and left lower lip (mandibular trigeminal division, V3) in 14 healthy volunteers during acquisition of whole-brain fMRI images. During V1 and V3 stimulation the fMRI signal in the primary (SI) and secondary (SII) somatosensory cortices in the contralateral hemisphere increased. Within both SI and SII, the foci activated by stimulation of the two trigeminal divisions largely overlapped. In contrast, the ipsilateral representation differed. Whereas V3 stimulation activated the contralateral somatosensory cortex alone, V1 stimulation activated SI and SII bilaterally. These results to some extent contrast with electrophysiological data in monkeys and disclose distinct cortical representations within facial territories in humans.

© 2003 Elsevier Science (USA). All rights reserved.

Keywords: Trigeminal system; fMRI; Primary somatosensory cortex; Secondary somatosensory cortex; Ipsilateral representation

Introduction

The cortical organization of the trigeminal somatosensory system has been studied in man using different techniques, i.e., direct cortical stimulation (Penfield and Jasper, 1954), dipolar analysis on magnetoencephalography (MEG) data (Karhu et al., 1991; Mogilner et al., 1994; Nakamura et al., 1998; Maeda et al., 1999; Suzuki et al., 2002), PET (Fox et al., 1987; Bittar et al., 1999), and fMRI (Servos et al., 1999; Stippich et al., 1999; Vincent et al., 2001). In the classical face representation of the somatosensory homunculus originally described by Penfield and Boldrey (1937) the forehead regions lie in a superior position and the lower lip regions in an inferior position along the central sulcus, with the tongue and eyes represented bilaterally. Whether this organization is correct is still controversial. Direct recordings from the somatosensory cortex in monkeys (Kaas et al., 1979; Nelson et al., 1980; Manger et al., 1995, 1996), as well as clinical and imaging findings in man (Ramachandran et al., 1992; Ramachandran and Hirstein, 1998;

Servos et al., 1999; Vincent et al., 2001), have shown that the face representation within the primary somatosensory cortex (SI) is much more complex than the one depicted in the classical somatosensory homunculus. Few studies have specifically addressed the activation of the secondary somatosensory cortex (SII) or the bilaterality of facial representation in SI and SII.

In order to obtain physiological information about the somatotopic representation of the face in the somatosensory cortices, we studied with functional MRI the contra- and ipsilateral cerebral responses to repetitive tactile stimulation of the forehead region (ophthalmic trigeminal division, V1) and lower lip (mandibular trigeminal division, V3) in normal subjects.

Methods

Subjects

Fourteen healthy volunteers (6 women, 8 men) aged between 24 and 32 years (mean 26.1 years) participated in the study. All subjects gave their informed consent and the research was approved by the local Ethical Committee.

* Corresponding author. Dipartimento Scienze Neurologiche, Viale Università, 30-00185 Roma, Italy. Fax: +39-06-49914758.

E-mail address: cruccu@uniroma1.it (G. Cruccu).

Stimulation protocol

We stimulated the skin in two trigeminal divisions on the left side of the face: the forehead region (V1) and the lower lip (V3). We took care to ensure reproducibility of site, frequency, and intensity of stimulation across runs and subjects. V1 stimulation consisted of stroking up and down at about 2 Hz the skin of the forehead with a cotton-tipped swab within a longitudinal 3×2 -cm area just above the eyebrow. V3 stimulation consisted of a similar stroking of the skin of the lower lip within a diagonally oriented 3×2 -cm area. The medial border of these areas was kept 2 cm lateral to the midline. The stimulation areas were drawn on the subject's skin with a felt pen. To minimize the variability of the stimuli, these were always delivered by the same experimenter, who had been specifically trained before. Inside the scanner room the experimenter kept his hand resting on the coil surface, holding a long cotton-tipped swab that reached the skin through the coil. To avoid passive movements of the subject's head this was restrained with foam padding and straps. Immediately before the fMRI acquisition session, a stimulation trial was performed and subjects were asked to report whether the sensation was clear and constant.

Subjects were instructed to remain relaxed with their eyes closed and to keep their attention on the tactile stimuli. During an open interview at the end of each run, subjects described their perceived sensation, that was usually reported as a gentle and clear stroking. One run was repeated because the subject reported that stimulation was not constant.

For each subject, during the same fMRI recording session two distinct acquisition blocks (one run for each trigeminal division) were performed. Each run had a standard block-designed configuration, consisting of multiple 15-s periods of baseline (OFF) and stimulation (ON), in a boxcar configuration, for a total of 7 OFF/ON epochs. The beginning and end of stimulation periods were communicated to the experimenter through the scanner earphones. The order of the stimulated divisions was randomized and balanced between subjects.

Imaging and data analysis

fMRI experiments were performed using a 1.5-T whole body scanner (Philips Gyroscan). T2*-weighted echo planar images (64×64 matrix, over a 240 mm field of view) were acquired from 25 consecutive axial sections (slice thickness 4 mm, TR/TE = 3000/50 ms, flip angle 90° , and one single excitation). During each run a total of 75 consecutive dynamics (3 s each) were acquired; the first 5 images of the series were discarded. High-resolution 3D T1-weighted anatomical images (TR/TE = 30/4.6 ms, 256×256 matrix, flip angle 30°) were acquired in the same orientation of the functional images, producing 120 consecutive axial images with a slice thickness of 1 mm.

We used SPM99 (<http://www.fil.ion.ucl.ac.uk/spm>) for image processing and statistical analysis of the fMRI time series data. All images were realigned to the first, corrected for motion artifacts, normalized into the Montreal Neurological Institute (MNI) stereotactic space (Evans et al., 1993) and smoothed with an 8-mm FWHM Gaussian kernel. Motion parameters were checked for each subject, in order to ascertain that they did not exceed 1 mm in translation and 1.5° in rotation. Activated voxels were identified with the general linear model approach for time series data (Friston et al., 1995), using a delayed boxcar model function. Data for each individual were then analyzed to detect signal changes significantly related to cortical neural events elicited by the trigeminal stimulation. A *t* statistic was used to determine significance on a voxel-by-voxel basis and the data were transformed into a normal distribution (*Z* statistic). Regions of significant condition-associated signal changes were then displayed with a statistical threshold based on the amplitude ($P < 0.05$, corrected for multiple comparisons) and extent (80 mm^3) of the regions of activation (Friston et al., 1995). Within them, the location of the most significant voxels was expressed with their coordinates in the Talairach's space (Talairach and Tournoux, 1988).

A second-level group analysis, threshold at $P < 0.05$ corrected for multiple comparisons and cluster volume $>80 \text{ mm}^3$, was performed for each stimulated district using a random-effect approach, in order to obtain information about activations which could be consistent for the entire group. On the basis of an a priori hypothesis, the significance of activations was corrected for a brain volume including the pre- and postcentral gyrus and the parietal operculum of the two hemispheres, identified on high-resolution T1 images.

To analyze the time course of BOLD signal intensity changes within the somatosensory cortices, we a priori defined four regions of interest (ROIs) on the anatomical images of each subject; each ROI corresponded to one of the four sites of significant activations revealed by the group analysis, in the contralateral and ipsilateral SI and SII (see Results). The mean normalized signal intensity of the voxels included in each ROI was calculated for each subject.

Furthermore, to separate the activations in the somatosensory cortex from those in the motor cortex, we defined on the anatomical template two additional adjacent ROIs bordering the central sulcus at the level of the face representation, one in the postcentral gyrus (postCG) and one in the precentral gyrus (preCG).

Results

Single-subject analysis

The data regarding the activations in individual subjects are summarized in Table 1. Repetitive tactile stimulation of V3 produced multiple activation sites in the postCG of the

Table 1
Individual frequencies of activation in postcentral cortex during trigeminal stimulation

Stimulated division	Number of subjects	Contralateral hemisphere	Ipsilateral hemisphere
V3	14	11/14 (79%)	5/14 (36%)
V1	14	12/14 (86%)	10/14 (71%)

contralateral hemisphere in 11/14 subjects (79%). In 6 subjects the activation extended to the central sulcus, showing a combined involvement of both postCG and preCG. The ipsilateral hemisphere was activated in 5/14 subjects (36%), and a combined activation of both ipsilateral postCG and preCG was found in one subject.

V1 tactile stimulation produced multiple activation sites in the postCG of the contralateral hemisphere in 12/14 subjects (86%). In 7 subjects the activation extended to the central sulcus, showing a combined involvement of both postCG and preCG. The ipsilateral hemisphere was activated in 10/14 subjects (71%), and a combined activation of both ipsilateral PostCG and PreCG was detected in 5 subjects.

Group analysis

The group analysis ($P < 0.05$, corrected for multiple comparisons) revealed that both V3 and V1 stimulation led to two distinct foci on the contralateral parietal lobe (Table 2). The first active cluster was located within the anterior wall of the contralateral postcentral gyrus (postCG), near the central sulcus (CS), likely corresponding to the Brodmann area (BA) 3b of SI (Geyer et al., 1999). The other active cluster was located in the superior bank of the Sylvian fissure (BAs 40/43), corresponding to the contralateral SII. The active clusters observed in SI and SII following V3 and V1 stimulation largely overlapped, and their centroids almost coincided (Fig. 1, Table 2).

All the active clusters found in the contralateral hemisphere after V1 stimulation were also found in roughly symmetrical regions of the ipsilateral hemisphere (i.e., ipsilateral postCG and superior bank of the Sylvian fissure) (Fig. 2, Table 2). The analysis of the two ROIs drawn to separate motor from somatosensory cortical activations revealed that part of the “SI cluster” corresponded to the preCG, for both V3 (contralateral hemisphere: 54%) and V1 stimulations (contralateral hemisphere: 58%, ipsilateral hemisphere: 50%).

Fig. 3 shows how the signal time course differed in the ipsilateral SI and SII voxels after V1 and V3 stimulation.

Discussion

Trigeminal tactile stimuli clearly activated the contralateral SI and SII areas. The areas activated by lower lip and

forehead stimulations largely overlapped in both SI and SII. The main difference between lower lip and forehead activations was that forehead stimuli yielded a symmetrical activation of SI and SII in both hemispheres, whereas lower lip stimuli produced a far higher activation in the contralateral hemisphere.

Face somatotopy within the contralateral parietal cortex

We found overlap of V1 and V3 representations in SI. This is in contrast with the classical somatosensory homunculus originally described by Penfield and colleagues (Penfield and Boldrey, 1937; Penfield and Rasmussen, 1950; Penfield and Jasper, 1954), which had the lower lip closer to the Sylvian fissure and the forehead more superior and medial. As noted in the Introduction, however, there is converging evidence that the face representation within SI is quite more complex or even different than described in the classical homunculus. For instance, microelectrode recordings in the monkey, that provide somatosensory maps with a far higher spatial resolution than fMRI (e.g., less than 1 mm, Manger et al., 1996), showed that the cortical fields responding to stimulation of different facial territories have an irregular shape and lie intermingled (Manger et al., 1995). If the same pattern holds true for the human cortex, our tactile stimuli activated multiple neural clusters that may well be sparse and intermingled within SI, thus resulting in the overlapping that we found in our fMRI study.

According to fMRI (Gelbar et al., 1998; Disbrow et al., 2000; Ruben et al., 2001) and MEG (Hari et al., 1993; Mima et al., 1997; Maeda et al., 1999) findings, SII appears to be somatotopically organized, although less precisely than SI, in humans. The present data confirm that, within SII, the face representation is located lateral in the parietal operculum, toward the hemispheric surface.

Bilateral representation of forehead tactile input

An interesting result of this study was that V1 stimulation yielded significant activations bilaterally, with the cor-

Table 2
Spatial location and extent of cortical clusters showing significant signal changes during trigeminal stimulation

	V3 stimulation				V1 stimulation					
	Vol	Z	x	y	z	Vol	Z	x	y	z
Contralateral hemisphere										
Sensorimotor cortex	464	5.42	59	-14	32	648	5.81	58	-18	34
Parietal Operculum	344	5.40	61	-12	24	416	5.38	63	-16	23
Ipsilateral hemisphere										
Sensorimotor cortex	—	—	—	—	—	408	5.68	-57	-15	32
Parietal Operculum	—	—	—	—	—	632	5.77	-69	-12	23

Volume (vol) of activations is expressed in mm³; Talairach coordinates (x, y, z) of peak foci of activation are expressed in mm.

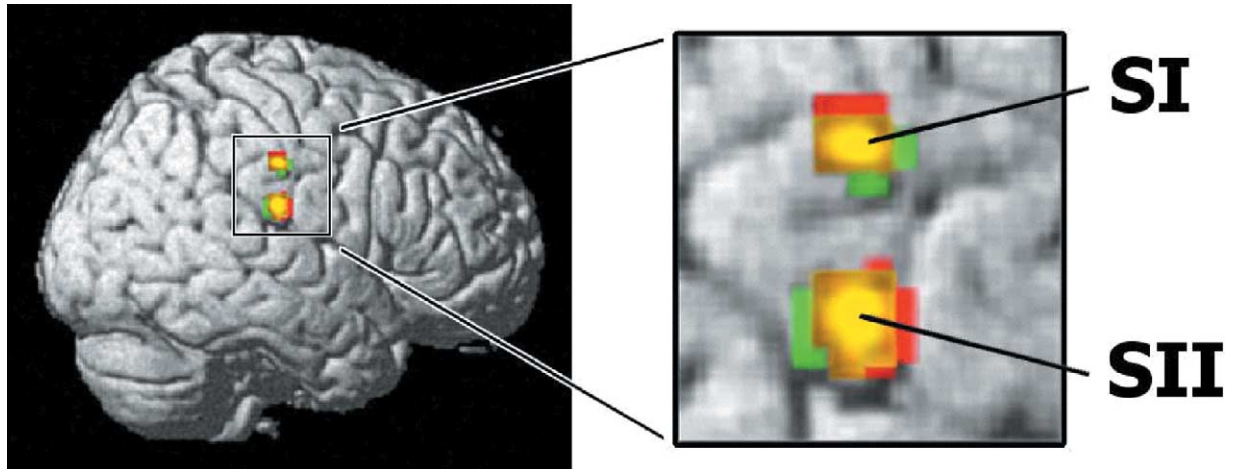
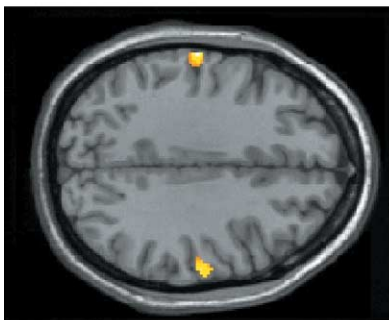


Fig. 1. Areas of significant activation in the contralateral hemisphere during tactile stimulation. Clusters activated by forehead stimulation are displayed in red, those activated by lower-lip stimulation are displayed in green. The regions activated both by V1 and V3 stimulation are displayed in yellow. Note that regions activated by V1 and V3 stimulations overlap both in SI and in SII.

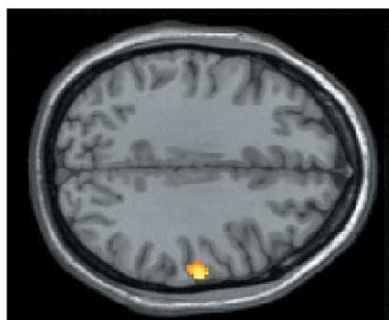
tical fields corresponding to ipsilateral SI and SII roughly symmetrical to the contralateral active clusters. In contrast, the activation induced by V3 stimulation did not reach group statistical significance in the ipsilateral hemisphere.

A bilateral activation of the human SII has been reported in several studies using different techniques. Direct surface recordings from the exposed cortex during surgery and dipolar analysis on MEG data showed bilateral activation of

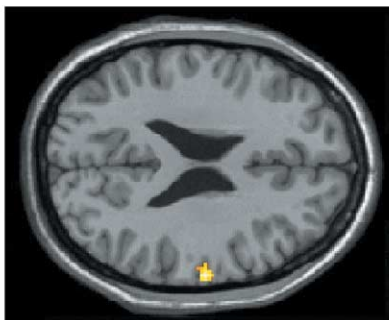
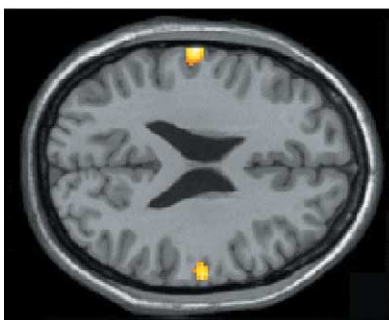
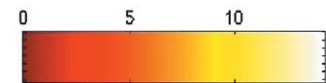Forehead (V1) stimulation



Lower lip (V3) stimulation



SI (z = 34)



SII (z = 24)

Fig. 2. Axial sections through primary (SI) and secondary (SII) somatosensory cortices showing the results of group analysis ($P < 0.05$, corrected for multiple comparisons). Tactile stimulation of both forehead (V1) and lower lip (V3) activated the contralateral SI and SII, but only the forehead stimulation yielded significant activations in the ipsilateral SI and SII.

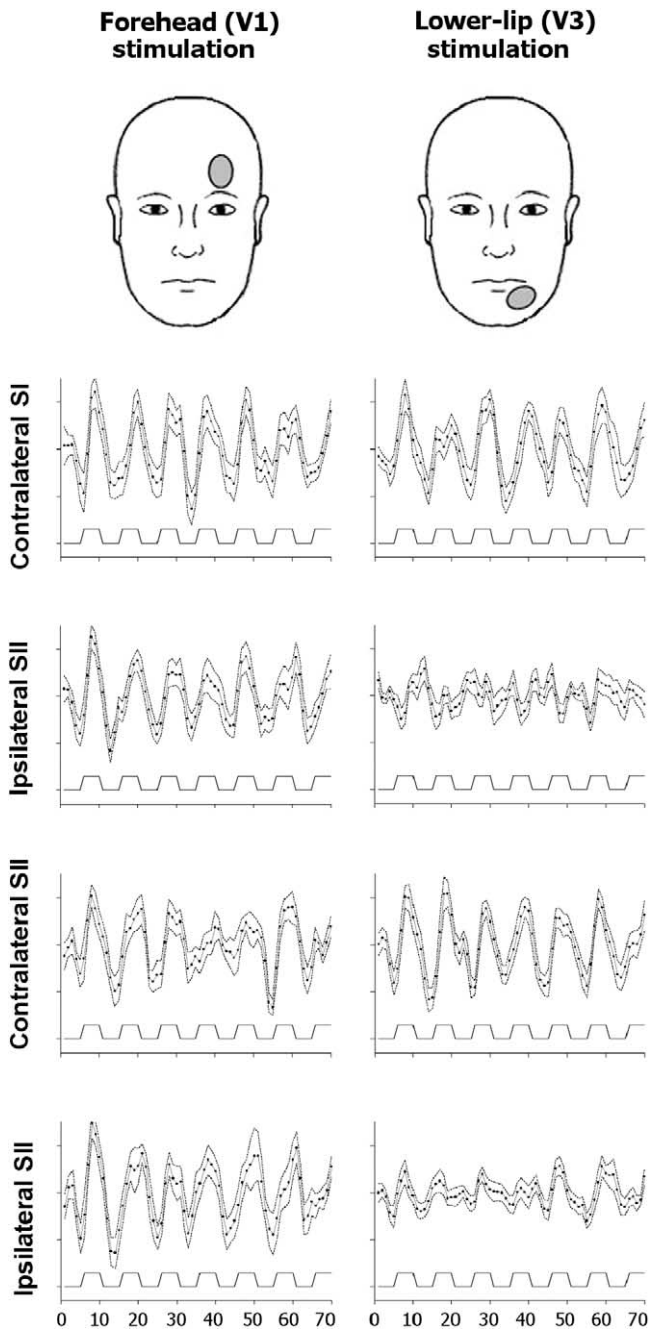


Fig. 3. Time profile of mean signal intensity during trigeminal tactile stimulation in contralateral and ipsilateral SI and SII. Each point represents mean \pm SEM ($n = 14$). In the contralateral SI and SII the signal intensity changes paralleled the stimulation paradigm during both V1 and V3 stimulations. In the ipsilateral SI and SII the signal intensity changes paralleled the stimulation paradigm during V1, but not during V3 stimulation.

SII after electrical stimulation of the hand (Allison et al., 1989; Hari et al., 1993; Kany and Treede, 1997), although the amplitudes of the responses were often higher on the contralateral than the ipsilateral side and several subjects had a contralateral activation only. Most PET and fMRI studies yielded similar results, showing a predominant or exclusive activation in the contralateral SII (Burton et al.,

1993; Coghill et al., 1994; Ledberg et al., 1995; Lin et al., 1996; Burton et al., 1997; Maldjian et al., 1999; Francis et al., 2000; Ruben et al., 2001). Even in fMRI studies describing an ipsilateral activation of SI after somatosensory stimulation of one hand (Hansson and Brismar, 1999; Korvenoja et al., 1999; Spiegel et al., 1999) the number of subjects having an ipsilateral SI activation was small, and the intensity of the signal changes was lower than those in the contralateral hemisphere (about 5 times lower in the study by Hansson and Brismar, 1999).

None of the PET or fMRI studies in humans, however, dealt with symmetry of facial cortical representations. One fMRI study in macaque monkeys, using exactly our kind of tactile stimulation of the lower lip, found that the activation of SI and SII was exclusively contralateral (Hayashi et al., 1999).

Microelectrode recordings from monkeys have shown the presence of neural activity in SI during stimulation of bilateral or ipsilateral receptive fields located in the midline territories of the body (Manzoni et al., 1989; Taoka et al., 1998). Iwamura and co-workers described, in awake monkeys, a number of SI neurons with bilateral receptive fields in distal territories like the hand digits or feet (Iwamura et al., 1994, 2002), and interpreted this bilateral activity as the neural substrate for the coordination of those movements that must be bilaterally coordinated. In the facial territory, most investigators found a bilateral representation for the intraoral region only (Mountcastle and Henneman, 1952; Schwarz and Fredrickson, 1971; Manger et al., 1995, 1996). These studies, however, were not specifically addressed to investigate and could not solve the problem of a possible bilateral representation of the forehead, because of the very small sample of cortical neurons responding to forehead stimulation.

During forehead stimulation we took care to remain lateral enough to exclude the paramedian skin that could be innervated by medial branches of the contralateral supraorbital nerve; indeed we stroked the skin in the same position recommended for the unilateral activation of the supraorbital nerve in blink reflex studies, where a stimulus spread to contralateral nerve branches is immediately disclosed by the appearance of a contralateral R1 response (Kimura et al., 1999; Cruccu and Deuschl, 2000). Hence our input was conveyed through the ipsilateral trigeminal root to the brainstem and relayed to the ipsilateral trigeminal principal sensory nucleus. Most of the trigemino-thalamic neurons cross the midline and reach the ventro-posterior-medial nucleus (VPM) in the contralateral thalamus; hence, somatosensory information eventually reaches the contralateral parietal cortex. Only neurons responding to intraoral stimuli have so far been found in the ipsilateral VPM of lower mammals and monkeys (Bombardieri et al., 1975; Jones et al., 1986). It can therefore be hypothesized that a great deal of the ipsilateral cortical activation is mediated by transcallosal projections from the contralateral cortex.

Why the cortical somatosensory representation of the

forehead is bilateral and that of the perioral skin mainly contralateral is not easily explained. It is known that, in humans, the cortical innervation for the upper facial motoneurons is bilateral and that for the lower facial motoneurons is contralateral, as suggested by the common clinical features of the supranuclear palsy and demonstrated using various techniques like direct stimulation of the exposed motor cortex (Penfield and Rasmussen, 1950), anatomical studies (Kuypers, 1958), and transcranial magnetic stimulation of the cortico-facial projections (Cruccu et al., 1990; Urban et al., 2001). In the cranial district, a predominantly contralateral innervation is directed to those nuclei innervating muscles that can be contracted unilaterally (e.g., jaw-closers and lower facial muscles), while bilateral projections from the cortex mostly reach the nuclei innervating muscles that cannot be contracted unilaterally (e.g., jaw-openers, laryngeal, palatal, and frontal muscles) (Kuypers, 1981; Cruccu et al., 1989). Hence the cortical organization of the human sensory trigeminal system seems to parallel that of the motor trigeminal and facial system. Because the sensory input plays a key role in the control of voluntary movements, the facial motor system may take advantage from a similar organization in the sensorimotor cortex. Similarly, the wider representation of the supraorbital territory in the somatosensory cortex in humans than in monkeys may reflect the peculiar human ability to perform fine and precise movements of the eyebrows contributing to communication through facial expression.

References

- Allison, T., McCarthy, G., Wood, C.C., Williamson, P.D., Spencer, D.D., 1989. Human cortical potentials evoked by stimulation of the median nerve. II. Cytoarchitectonic areas generating long latency activity. *J. Neurophysiol.* 62, 711–722.
- Bittar, R.G., Olivier, A., Sadikot, A.F., Andermann, F., Comeau, R.M., Cyr, M., Peters, T.M., Reutens, D.C., 1999. Localization of somatosensory function by using positron emission tomography scanning: a comparison with intraoperative cortical stimulation. *J. Neurosurg.* 90, 478–483.
- Bombardieri, R.A., Johnson, J.I., Campos, G.B., 1975. Species differences in mechanosensory projections from the mouth to the ventrobasal thalamus. *J. Comp. Neurol.* 163, 41–63.
- Burton, H., Videen, T.O., Raichle, M.E., 1993. Tactile-vibration-activated foci insular and parietal-opercular cortex studied with positron emission tomography: mapping the second somatosensory area in humans. *Somatosensory Motor Res.* 10, 297–308.
- Burton, H., MacLeod, A.M., Videen, T.O., Raichle, M.E., 1997. Multiple foci in parietal and frontal cortex activated by rubbing embossed grating patterns across fingerpads: a positron emission tomography study in humans. *Cereb. Cortex* 7, 3–17.
- Coghill, R.C., Talbot, J.D., Evans, A.C., Meyer, E., Gjedde, A., Bushnell, M.C., Duncan, G.H., 1994. Distributed processing of pain and vibration by the human brain. *J. Neurosci.* 14, 4095–4108.
- Cruccu, G., Berardelli, A., Inghilleri, M., Manfredi, M., 1989. Functional organization of the trigeminal motor system in man. A neurophysiological study. *Brain* 112, 1333–1350.
- Cruccu, G., Berardelli, A., Inghilleri, M., Manfredi, M., 1990. Cortico-bulbar projections to upper and lower facial motoneurons. A study by transcranial magnetic stimulation in man. *Neurosci. Lett.* 117, 68–73.
- Cruccu, G., Deuschl, G., 2000. The clinical use of brainstem reflexes and hand-muscle reflexes. *Clin. Neurophysiol.* 111, 371–387.
- Disbrow, E., Roberts, T., Krubitzer, L., 2000. Somatotopic organization of cortical fields in the lateral sulcus of *Homo sapiens*: evidence for SII and PV. *J. Comp. Neurol.* 418, 1–21.
- Evans, A.C., Collins, D.L., Mills, S.R., Brown, E.D., Kelly, R.L., Peters, T.M., 1993. 3D statistical neuroanatomical models from 305 MRI volumes. *Proc. IEEE Nuclear Science Symposium and Medical Imaging*, 1993, pp. 1813–1817.
- Fox, P.T., Burton, H., Raichle, M., 1987. Mapping human somatosensory cortex with positron emission tomography. *J. Neurosurg.* 67, 34–43.
- Francis, S.T., Kelly, E.F., Bowtell, R., Dunseath, W.J., Folger, S.E., McGlone, F., 2000. fMRI of the responses to vibratory stimulation of digit tips. *NeuroImage* 11, 188–202.
- Friston, K.J., Holmes, A.P., Poline, J.B., Grasby, P.J., Williams, S.C.R., Frackowiak, R.S.J., Turner, R., 1995. Analysis of fMRI time-series revisited. *NeuroImage* 2, 45–53.
- Gelnar, P.A., Krauss, B.R., Szeverenyi, N.M., Apkarian, A.V., 1998. Fingertip representation in the human somatosensory cortex: an fMRI study. *NeuroImage* 7, 261–283.
- Geyer, S., Schleicher, A., Zilles, K., 1999. Areas 3a, 3b and 1 of primary somatosensory cortices. *NeuroImage* 10, 63–83.
- Hansson, T., Brismar, T., 1999. Tactile stimulation of the hand causes bilateral cortical activation: a functional magnetic resonance study in humans. *Neurosci. Lett.* 271, 29–32.
- Hari, R., Karhu, J., Hamalainen, M., Knuttila, J., Salonen, O., Sams, M., Vilkmann, V., 1993. Functional organization of the human first and second somatosensory cortices: a neuromagnetic study. *Eur. J. Neurosci.* 5, 724–734.
- Hayashi, T., Konishi, S., Hasegawa, I., Miyashita, Y., 1999. Mapping of somatosensory cortices with functional magnetic resonance imaging in anaesthetized macaque monkeys. *Eur. J. Neurosci.* 11, 4451–4456.
- Iwamura, Y., Iriki, A., Tanaka, M., 1994. Bilateral hand representation in the postcentral somatosensory cortex. *Nature* 369, 546–554.
- Iwamura, Y., Tanaka, M., Iriki, A., Taoka, M., Toda, T., 2002. Processing of tactile and kinesthetic signals from bilateral sides of the body in the postcentral gyrus of awake monkeys. *Behav. Brain Res.* 135, 185–190.
- Jones, E.G., Schwark, H.D., Callahan, P.A., 1986. Extent of the ipsilateral representation in the ventral posterior medial nucleus of the monkey thalamus. *Exp. Brain Res.* 63, 310–320.
- Kaas, J.H., Nelson, R.J., Sur, M., Lin, C.S., Merzenich, M.M., 1979. Multiple representations of the body within the primary somatosensory cortex of primates. *Science* 204, 521–523.
- Kany, C., Treede, R.D., 1997. Median and tibial nerve somatosensory evoked potentials: middle-latency components from the vicinity of the secondary somatosensory cortex in humans. *Electroencephalogr. Clin. Neurophysiol.* 104, 402–410.
- Karhu, J., Hari, R., Lu, S.T., Paetau, R., Rif, J., 1991. Cerebral magnetic fields to lingual stimulation. *Electroencephalogr. Clin. Neurophysiol.* 80, 459–468.
- Kimura, J., Daube, J., Burke, D., Hallett, M., Cruccu, G., Ongerboer de Visser, B.V., Yanagisawa, N., Shimamura, M., Rothwell, J., 1999. Human reflexes and late responses. Report of an IFCN committee. *Electroencephalogr. Clin. Neurophysiol.* 52, 249–253.
- Korvenoja, A., Huttunen, J., Salli, E., Pohjonen, H., Martinkauppi, S., Palva, J.M., Lauronen, L., Virtanen, J., Ilmoniemi, R.J., Aronen, H.J., 1999. Activation of multiple cortical areas in response to somatosensory stimulation: combined magnetoencephalographic and functional magnetic resonance imaging. *Hum. Brain Mapp.* 8, 13–27.
- Kurth, R., Villringer, K., Curio, G., Wolf, K.J., Krause, T., Repenthin, J., Schwieemann, J., Deuchert, M., Villringer, A., 2000. fMRI shows multiple somatotopic digit representations in human primary somatosensory cortex. *NeuroReport* 11, 1487–1493.
- Kurth, R., Villringer, K., Mackert, B.M., Schwieemann, J., Braun, J., Curio, G., Villringer, A., Wolf, K.J., 1998. fMRI assessment of somatotopy in human Brodmann area 3b by electrical finger stimulation. *NeuroReport* 9, 207–212.

- Kuypers, H.G.J.M., 1958. Corticobulbar connexions to the pons and lower-brainstem in man: an anatomical study. *Brain* 81, 364–388.
- Kuypers, H.G.J.M., 1981. Anatomy of the descending pathways, in: Brookhart, J.M., Mountcastle, V.B. (Eds.), *Handbook of Physiology*, Vol. 2, Am. Physiol. Soc., Bethesda, MD, pp. 597–666.
- Ledberg, A., O'Sullivan, B.T., Kinomura, S., Roland, P.E., 1995. Somatosensory activations of the parietal operculum of man. A PET study. *Eur. J. Neurosci.* 7, 1934–1941.
- Lin, W., Kuppasamy, K., Haacke, E.M., Burton, H., 1996. Functional MRI in human somatosensory cortex activated by touching textured surfaces. *J. Magn. Reson. Imaging* 6, 565–572.
- Maeda, K., Kakigi, R., Hoshiyama, M., Koyama, S., 1999. Topography of the secondary Somatosensory cortex in humans: a magnetoencephalographic study. *Neuroreport* 10, 301–306.
- Maldjian, J.A., Gottschalk, A., Patel, R.S., Pincus, D., Detre, J.A., Alsop, D.C., 1999. Mapping of secondary somatosensory cortex activation induced by vibrational stimulation: an fMRI study. *Brain Res.* 824, 291–295.
- Manger, P.R., Woods, T.M., Jones, E.G., 1995. Representation of the face and intra-oral structures in area 3b of the squirrel monkey (*Saimiri sciureus*) somatosensory cortex, with special reference to the ipsilateral representation. *J. Comp. Neurol.* 363, 597–607.
- Manger, P.R., Woods, T.M., Jones, E.G., 1996. Representation of face and intra-oral structures in area 3b of macaque monkey somatosensory cortex. *J. Comp. Neurol.* 371, 513–521.
- Manzoni, T., Barbaresi, P., Conti, F., Fabri, M., 1989. The callosal connections of the primary somatosensory cortex and the neural bases of midline fusion. *Exp. Brain Res.* 76, 251–266.
- Mogilner, A., Nomura, M., Ribary, U., Jagor, R., Lado, F., Rusinek, H., Llinas, R., 1994. Neuromagnetic studies of the lip area of primary somatosensory cortex in humans: evidence for an oscillotopic organization. *Exp. Brain Res.* 99, 137–147.
- Mountcastle, V.B., 1995. Central nervous mechanisms in mechanoreceptive sensibility, in: *Handbook of Physiology, The Nervous System, Sensory Processes*, Vol. III, Am. Physiol. Soc., Bethesda, MD, pp. 789–878.
- Mountcastle, V.B., Henneman, E., 1952. The representation of tactile sensibility in the thalamus of the monkey. *J. Comp. Neurol.* 97, 409–440.
- Nakamura, A., Yamada, T., Goto, A., Kato, T., Ito, K., Abe, Y., Kachi, T., Kakigi, R., 1998. Somatosensory homunculus as drawn by MEG. *NeuroImage* 7, 377–386.
- Nelson, R.J., Sur, M., Felleman, D.J., Kaas, J.H., 1980. Representations of the body surface in postcentral parietal cortex of *Macaca fascicularis*. *J. Comp. Neurol.* 192, 611–643.
- Penfield, W., Boldrey, E., 1937. Somatic motor and sensory representation in the cerebral cortex of man as studied by electrical stimulation. *Brain* 60, 389–443.
- Penfield, W., Jasper, H., 1954. *Epilepsy and the Functional Anatomy of the Human Brain*. Little, Brown, Boston.
- Penfield, W., Rasmussen, T., 1950. *The Cerebral Cortex of Man*. Macmillan, New York, pp. 11–65.
- Ramachandran, V.S., Hirstein, W., 1998. The perception of phantom limbs. *Brain* 121, 1603–1630.
- Ramachandran, V.S., Stewart, M., Rogers-Ramachandran, D.C., 1992. Perceptual correlates of massive cortical reorganization. *NeuroReport* 3, 583–586.
- Ruben, J., Schwiemann, J., Deuchert, M., Meyer, R., Krause, T., Curio, G., Villringer, K., Kurth, R., Villringer, A., 2001. Somatotopic organization of human secondary somatosensory cortex. *Cereb. Cortex* 11, 463–473.
- Schwarz, D.M., Fredrickson, J.M., 1971. Tactile direction sensitivity of area 2 oral neurons in the rhesus monkey cortex. *Brain Res.* 27, 397–401.
- Servos, P., Engel, S.A., Gati, J., Menon, R., 1999. fMRI evidence for an inverted face representation in human somatosensory cortex. *NeuroReport* 10, 1393–1395.
- Spiegel, J., Tintera, J., Gawehn, J., Stoeter, P., Treede, R.D., 1999. Functional MRI of human primary somatosensory and motor cortex during median nerve stimulation. *Clin. Neurophysiol.* 110, 47–52.
- Stippich, C., Hofmann, R., Kapfer, D., Hempel, E., Heiland, S., Jansen, O., Sartor, K., 1999. Somatotopic mapping of the human primary somatosensory cortex by fully automated tactile stimulation using functional magnetic resonance imaging. *Neurosci. Lett.* 277, 25–28.
- Suzuki, T., Shibukawa, Y., Kumai, T., Shintani, M., 2002. Face area of somatosensory cortex in humans identified by whole-head magnetoencephalography. *Neuroimage, Proc. Human Brain Mapping 2002 Meeting*, p. 782.
- Talairach, J., Tournoux, P., 1988. *Co-planar Stereotaxic Atlas of the Human Brain*. Thieme, Stuttgart.
- Taoka, M., Toda, T., Iwamura, Y., 1998. Representation of the the midline trunk, bilateral arms, and shoulders in the monkey postcentral somatosensory cortex. *Brain Res.* 123, 315–322.
- Urban, P.P., Wicht, S., Vucorevic, G., Fitzek, S., Marx, J., Thomke, F., Mika-Gruttner, A., Fitzek, C., Stoeter, P., Hopf, H.C., 2001. The course of corticofacial projections in the human brainstem. *Brain* 124, 1866–1876.
- Vincent, D., Roberts, M., Burkhalter, W., 2001. Functional magnetic resonance imaging studies of face representation in the normal human brain. *NeuroImage* 13, S1276.